



Short Metaphyseal Femoral Stem Total Hip Arthroplasty in Poor Quality Bone Cortex Without Neck Length Sparing: A Case Report

Aekkarith Khamkhad, MD

Department of Orthopedics, Rayong Hospital, Rayong, Thailand

Purpose: The principle of short metaphyseal femoral stem total hip arthroplasty (short stem THA) required the cortical ring of the femoral neck and lateral touch of the distal stem at the proximal femur, but this case had an improper cortical ring of the femoral neck and lateral touch.

Methods: A case report of a 39-year-old male who underwent short stem THA surgery owing to a failure of the femoral neck fixation and delayed union of the femoral shaft fracture.

Results: The patient reported successful 5-year clinical and radiographic outcomes for a short stem THA.

Conclusions: Short stem THA could be an alternative implant option, compared with conventional cementless stem, for young patients with good bone quality, despite lacking femoral neck anchoring, with superiority in terms of bone stock preservation and more natural loading.

Keywords: Short stem total hip arthroplasty, fixation failure in femoral neck fracture, ipsilateral neck-shaft fractures of femur, cortical femoral neck ring

Total hip arthroplasty (THA) was proposed by Smith-Petersen⁽¹⁾ and has become a frequent surgical procedure, providing excellent results in younger, more active patients with hip joint pathologies or traumatic femoral neck fractures. In recent years, short metaphyseal femoral stem total hip arthroplasty (short stem THA) has been an increasingly popular implant choice, providing better stress distribution and greater bone stock for subsequent conventional THA⁽²⁾. However, short stem THA has some limitations that surgeons should avoid using such

devices. Specifically, it should not be used in cases where there is a bone defect along with the length of the cortical ring femoral neck, both medial and lateral sides, with less than 5 mm of bone remaining or bone defect on the lateral side of the proximal femur. Due to the strength of the femoral stem, the 3-point fixation principle must be applied in this area⁽³⁾.

CASE REPORT

A 39-year-old male who smoked half a pack per day had a severe traffic accident with ipsilateral neck-shaft fractures of the right femur. Status postoperative closed reduction and internal fixation with multiple screws fixation of the right femoral neck and open reduction and internal fixation with board plate of the right femoral shaft for nine months with loosening multiple screws fixation of the femoral neck. There was a crescent sign on the femoral head, indicating osteonecrosis

Article history:

Received: August 4, 2023 Revised: January 13, 2025

Accepted: February 28, 2025

Correspondence to: Aekkarith Khamkhad, MD

Department of Orthopedics, Rayong Hospital, Rayong, Thailand

E-mail: meetoona@hotmail.com

of the femoral head and delayed union of the femoral shaft (Figure 1). Because of the bone necrosis at the femoral head, the patient smoked heavily. Therefore, the surgeons considered it most appropriate to perform total hip arthroplasty (THA) surgery, which was the option of surgery rather than refixation or valgus osteotomy. Additionally, THA in this patient had another advantage. The bone graft obtained from the femoral head could be inserted into the femoral shaft fracture, which delays union. However, in this patient, if using conventional THA, there was a chance that the femoral stem would collide or affect the screw fixation at the shaft of the femur, which was still delayed union, and the screws could not be removed. Therefore, it was necessary to choose short stem THA even though the neck length could not be set to 5 mm, and the quality of the lateral cortex of the proximal femur was poor owing to a bone defect from multiple screws fixation.

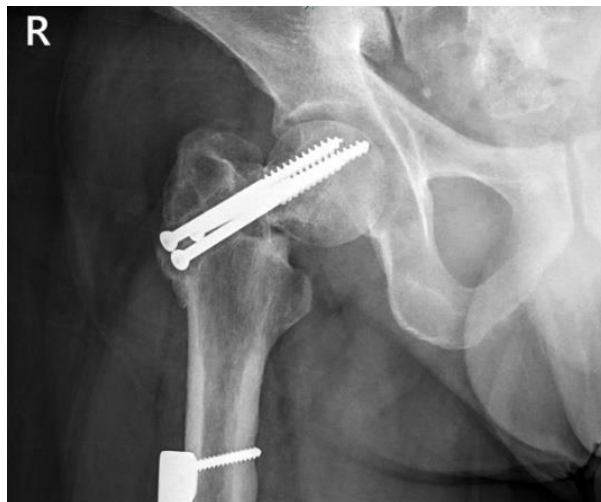

Fig. 1 Improper screws nearly protruding to the hip joint.

The short stem THA surgery was performed (Metha® features of B Braun (Thailand) co. Ltd.), in which Melicki M et al.⁽⁴⁾ and Thanut T et al.⁽⁵⁾ have reported the effectiveness of this device as having good results of treatment. The operation was performed through the posterior approach, and the multiple screws were exposed and removed, as well as the femoral head, which was

later prepared and used to promote femoral shaft fracture healing. The acetabulum cup was pressed-fit, one screw was inserted according to standard procedure, and the short cementless femoral stem was inserted, achieving the same level of the femoral head center as the tip of the greater trochanter. There was no postoperative complication. Standard routine care for the postoperative period included ankle pumping exercises, hip flexion/extension/abduction strengthening exercises, quadriceps strengthening exercises, and posterior hip precaution. Since there was also a non-united femoral shaft fracture, this patient was protected from weight bearing for three months before progressing to bear weight fully.

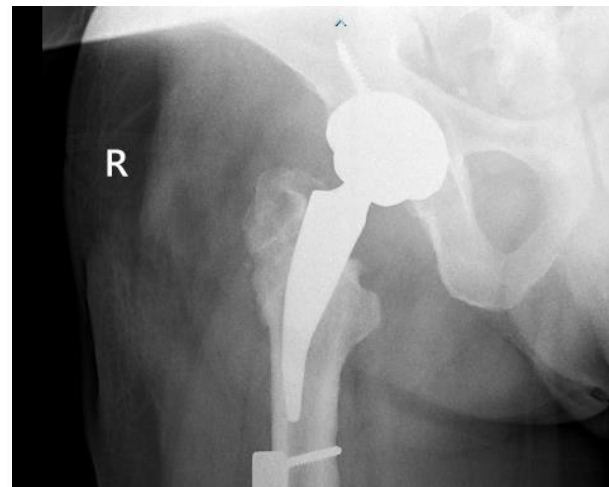


Fig. 2 The film one month after short stem THA showed no neck length sparing of a femoral stem with poor quality bone at the lateral cortex of proximal femur from multiple screws fixation.

One month after surgery, the femoral shaft began to form calluses on both AP and lateral sides, and short stem THA did not migrate or subside (Figure 2). The patient was allowed to bear full weight after three months of surgery. The X-ray was evaluated every three months in the first year after surgery, then every six months. Thereafter, complications were not detected, and the patient could resume his normal daily activities. Five years after short stem THA surgery, it was found that the femoral shaft had a complete union, and short stem

THA, especially the lateral cortex of the proximal femur, which had been eroded by the multiple screws, was healed with bone ingrowth. Although the film X-ray of both hip AP showed stable fibrous ingrowth at the lateral side of the stem; however, the medial side of the stem showed stable fixation by bone ingrowth. There was no sign of loosening, no limb length discrepancy, no subsidence, or migration of short stem THA (Figure 3). The patient had no clinical hip pain, was able to walk normally, and was very satisfied with the result of treatment, and the Harris hip score was 93.

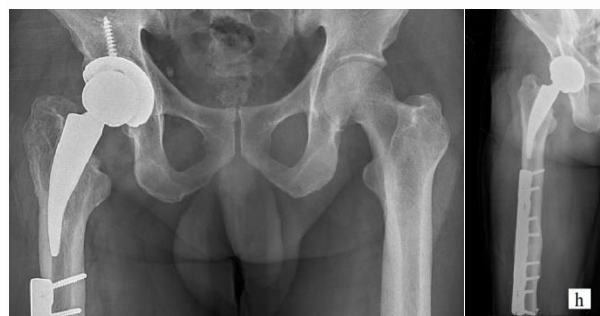

Fig. 3 The film five years after short stem THA.

DISCUSSION

Walker PS et al.⁽⁶⁾ have described the principle of force distribution of short stem THA, which required neck length sparing of the medial and lateral side and good quality of the lateral side of the proximal femur. However, in some cases, it is not possible to preserve sparing bone to produce 3-point fixation, requiring the use of short stem THA.

However, this patient showed satisfactory results with short stem THA. One possible explanation might be that we found the cortical ring

of the femoral neck in some patients that had a flat oval shape, with the result that the proximal stem had a stable fixation with the anterior and posterior neck instead of mediolateral. Three-point fixation in this patient might be at anterior and posterior neck and distal stem contact at the lateral part of the proximal femur, which is below the insertion point of the screws.

Literature Review of Short Stem THA

Short stem THA could be a useful tool for the total hip replacement procedure. Conventional stem requires stem length to ensure fixation; therefore, this complicates surgical plans in some conditions. Advantages of short stem THA include 1) the preservation of the femoral bone stock, which would be beneficial for a future revision, particularly in young patients, 2) a decrease in cortical stress and proximal stress shielding, which would also provide better biomechanics and long-term survival of the prosthesis, 3) the feasibility of the minimally invasive surgical technique, 4) viability of the alternative plan for femoral deformity/fracture requiring multiple types of implants⁽⁷⁻¹³⁾. Literature regarding the versatile uses of short stem THA was collected in the table below (Table 1).

CONCLUSIONS

Short stem THA might be a potential alternative for patients for whom conventional THA could not be used, such as in this patient. However, the intraoperative stability of the stem must be evaluated carefully, which is very essential in terms of stem survival.

Table 1 Literature review of short stem THA.

References	Cases	Condition	Implant	Follow-up period
Coutandin (2022)	6 patients (male, mean age 73 years)	failed conventional hip arthroplasty	Calcar-guided short stem optimys (Mathys. Bettlach, Switzerland)	3.32 ± 0.63 years
Thorate (2020)	55-year-old male	posterior hip dislocation along with aseptic loosening of the cemented acetabular component	Short stem high offset femoral component [SMF™ STIKTITE™, Smith & Nephew, Memphis (TN), USA]	2 years

Table 1 Literature review of short stem THA. (Cont.)

References	Cases	Condition	Implant	Follow-up period
Lee (2017)	65-year-old male	intraprosthetic fracture of the femoral stem	Proximal-filled short femoral stem	42 months
Moga (2014)	35-year-old male	Posttraumatic hip arthritis	Proxima prosthesis, with a short femoral stem	
Diamond (2013)	43 year-old female	Posttraumatic hip arthritis in below-knee amputated limb	Metha Short Hip Stem (B Braun®, Aesculap, AG, Tuttlingen, Germany)	2 years
Oh (2013)	43-year-old female, 52-year-old male	Postseptic hip sequele, Osteonecrosis with subtrochanteric fracture,	Modular short uncemented stem (Metha; B Braun®, Aesculap, Tuttlingen, Germany)	20 months
Kim (2010)	47-year-old male	Femoral neck-shaft fracture with osteonecrosis	Short cementless anatomical stem (PROXIMATM; DePuy, Leeds, UK)	5 years

REFERENCES

1. Smith-Petersen M, Larson C, Aufranc O, et al. Complications of old fractures of the neck of the femur; results of treatment of vitallium-mold arthroplasty. J Bone Joint Surg Am 1947;29:41-8.
2. Yan SG, Chevalier Y, Liu F, et al. Metaphyseal anchoring short stem hip arthroplasty provides a more physiological load transfer: a comparative finite element analysis study. J Orthop Surg Res 2020;15:498.
3. Rapeepat N, Pacharapol U. Cementless femoral component: Short metaphyseal stem. In: Thanainit C, editor. Textbook of total hip arthroplasty surgery. 1st Thai edition: Thai hip&knee society, RCOST; 2010. p.240-1.
4. Milecki M, Kowalczewski J, Wielopolski A, et al. Modular short-stem prosthesis in total hip arthroplasty: preliminary report. Chir Narzadow Ruchu Orthop Pol 2008;73:244-7.
5. Tippimanchai T, Suksathien Y, Suksathien R. Patient reported outcome in short stem total hip arthroplasty. JRCOST 2020;44:26-34.
6. Walker PS, Blunn GW, De Prada D, et al. Design rationale and dimensional considerations for a femoral neck prosthesis. Clin Orthop Relat Res 2005;441:313-9.
7. Coutandin M, Afghanyar Y, Rehbein P, et al. Downsizing in total hip arthroplasty. A short stem as a revision implant. Orthopade 2022;51:230-8.
8. Thorat B, Singh A, Vohra R. Role of a bone conserving short stem femoral component in revision total hip arthroplasty: A case report. J Clin Orthop Trauma 2020;14:29-33.
9. Lee PYF, Woodnutt DJ, Golding DM. A short femoral stem in revision total hip replacement: An alternative solution for prosthetic fracture: A case report. JBJS Case Connect 2017;7:e33.
10. Moga M, Pogarasteanu ME. Technical considerations and functional results in primary uncemented hip arthroplasty using short femoral stems through mini-invasive techniques. J Med Life 2014;7:403-7.

11. Diamond OJ, Mullan CJ, McAlinden MG, et al. Total hip arthroplasty following an ipsilateral above knee amputation. *Hip Int* 2013;23:104-7.
12. Oh KJ, Yang JH. Versatile application of short stem during total hip arthroplasty. *Eur J Orthop Surg Traumatol* 2013;23 Suppl 2:S229-32.
13. Kim TY, Lee KB, Kwon DJ, et al. Total hip arthroplasty using a short-stemmed femoral component in the presence of a proximal femoral fixation device - a case report. *Hip Int* 2010;20:261-4.