



A Randomized Prospective Study of Short-Term Complications Between Simple Release and Extensor Retinaculum Reconstruction in De Quervain's Tenosynovitis

Natdanai Chusing, MD

Department of Orthopaedics, Khon Kaen Hospital, Khon Kaen, Thailand

Purpose: To study and compare the postoperative complications of De Quervain's tenosynovitis treatment using two methods: simple release and extensor retinaculum reconstruction.

Methods: This randomized controlled trial included 24 patients divided into two groups: Group 1 (simple release) and Group 2 (extensor retinaculum reconstruction), with 12 patients in each group.

Results: The mean age of the participants was 51.75 and 49.25 years for Groups 1 and 2, respectively. The study participants included three males and 21 females. Intraoperatively, subcompartments were observed in two patients in Group 1 and six patients in Group 2. Additionally, a ganglion cyst in the tendon was found in one patient per group. The mean preoperative visual analog scale (VAS) and Disabilities of the Arm, Shoulder and Hand (DASH) scores for Group 1 were 7.83 and 61.44, respectively, whereas those for Group 2 were 8.17 and 66.52, respectively. Postoperatively, the VAS and DASH scores for Group 1 changed to 2.17 and 15.47, respectively, whereas those for Group 2 changed to 2.67 and 16.33, respectively ($p = 0.843$ and 0.63 , respectively). Tendon subluxation was observed in two patients in Group 1, with none in patients in Group 2 ($p = 0.14$).

Conclusions: No significant tendon subluxation was observed in either surgery type, with no significant differences in the treatment outcomes.

Keywords: De Quervain's tenosynovitis, simple release, extensor retinaculum reconstruction

De Quervain's tenosynovitis is a condition commonly encountered in working-age individuals and is often attributed to wrist overuse. Non-operative management typically involves administering local injections 2–3 times; however, if symp-

toms persist despite this method, surgical intervention may become necessary⁽¹⁻³⁾. The primary surgical approach involves simple release (SR) of the extensor retinaculum. However, some studies have reported tendon subluxation-induced discomfort during use⁽⁴⁻⁶⁾. Consequently, an alternative surgical method involving extensor retinaculum reconstruction (ERR) has been employed to mitigate this complication.

This research aimed to investigate tendon subluxation-related complications following surgery for De Quervain's tenosynovitis. We hypothesized that ERR results in fewer complications than SR.

Article history:

Received: February 27, 2024 Revised: July 15, 2024

Accepted: July 25, 2024

Correspondence to: Natdanai Chusing, MD

Hand and Microsurgery Unit, Department of Orthopedic Surgery, Khon Kaen Hospital, Khon Kaen, Thailand

E-mail: Natdanai30@gmail.com

MATERIALS AND METHODS

This study was approved by our institute and was conducted between March 2021 and October 2023. Inclusion criteria included participants aged >18 years who underwent a physical examination for De Quervain's tenosynovitis, with tenderness at the 1st dorsal compartment, and a positive Finkelstein's test was observed. Eligible patients received local corticosteroid injections two or more times without improvement or experienced symptom recurrence. Exclusion criteria encompassed individuals with underlying conditions such as rheumatoid arthritis, osteoarthritis of the 1st carpometacarpal joint, and median carpal tunnel syndrome.

The sample size was calculated using the N4studies version 1.4.2 program. Values were represented with reference to the research by Kim et al.⁽⁷⁾ as follows (using standard deviation values from complications in this study). Twenty-six patients participated in the study after providing informed consent and were categorized into two groups: participants in Group 1 underwent SR, and those in Group 2 underwent release with ERR. The participants were evenly distributed, with each group comprising 13 patients using computer-generated randomization. All surgeries were performed by a single surgeon at our institute. Postoperatively, one patient from each group was lost to follow-up, resulting in a final cohort of 12 patients per group. Pain and functional outcomes were assessed using the visual analog scale (VAS) and Disabilities of the Arm, Shoulder and Hand (DASH) scores preoperatively and 3 months postoperatively. Additionally, data on complications, such as tendon subluxation, wound infections, and injuries to the veins, tendons, and nerves were recorded. For postoperative tendon subluxation, the assessor measured the mobility of the tendon on the patient's skin around the wrist while it was flexed and extended (Fig. 4).

Demographic data were analyzed using means, medians, and percentage values. The chi-square test was employed for the complication analysis. The assessment of VAS and DASH scores preoperatively and 3 months postoperatively employed the Mann-Whitney U test. Statistical

analyses were performed using SPSS for Windows version 28.0.1.0, and the level of significance was set at $p < 0.05$.

Surgical Technique

The patient was placed in the supine position, and 2% xylocaine with adrenaline was injected approximately 1 cm proximal to the radial styloid. A 2–3 cm oblique skin incision was made over the 1st compartment. The superficial radial nerve was identified and protected. Similarly, the 1st dorsal compartment, along with the abductor pollicis longus and extensor pollicis brevis tendons, was identified (Fig. 1). Simple longitudinal release of the extensor retinaculum was performed in the control group. In the study group, ERR was performed using the Takagi technique. The first extensor retinaculum was cut in a step-cut manner, with the ends defined as the distal ulnar and proximal radial bases (Fig. 2). The extensor pollicis brevis and abductor pollicis longus tendons were explored, the subcompartmental septum and ganglion cyst were identified, and if present, the cyst was addressed and excised. In the study group, the distal and proximal retinacula were sutured together without tension (Fig. 3). Tendon movement toward the wrist was assessed in both groups by gently flexing and extending the wrist to observe volar subluxation. Postoperatively, patients were advised to move their wrists gently.

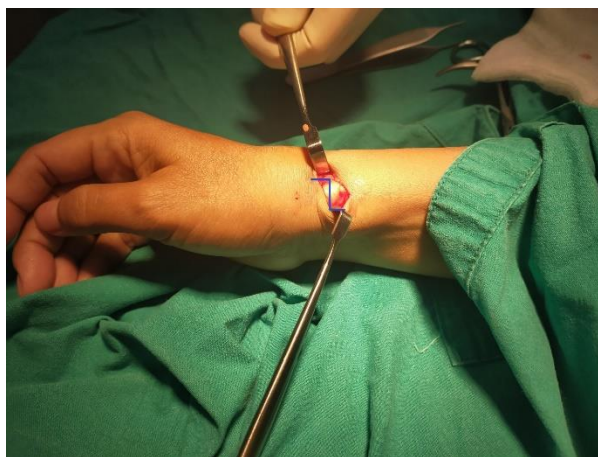


Fig. 1 Identifying the 1st dorsal compartment and planning the step-cut incision.

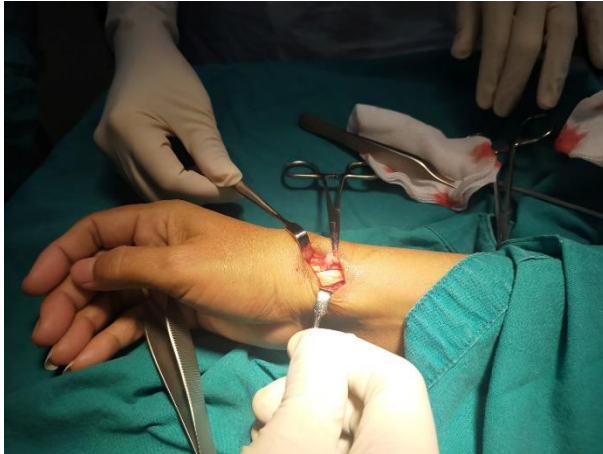

Fig. 2 The 1st extensor retinaculum is cut in a step cut, with the ends defined as the distal ulnar and proximal radial bases.

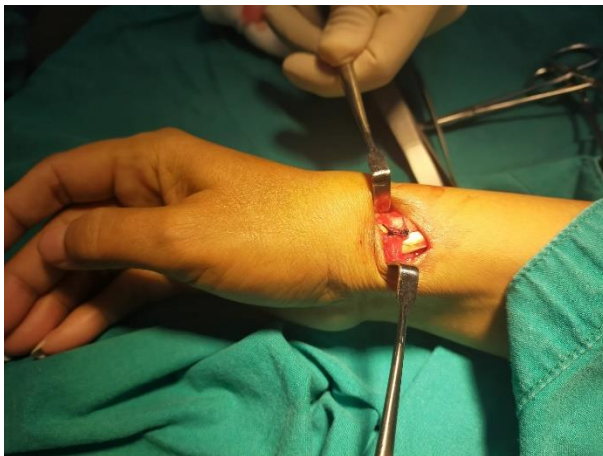


Fig. 3 The distal and proximal bases were sutured together without tension.

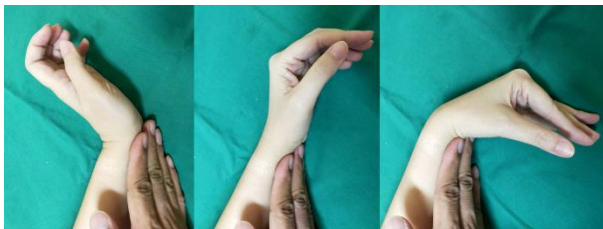

Fig. 4 Demonstration of physical examination of tendon subluxation. The examiner places their hand on the volar side of the patient's wrist while the wrist is extended. Then, the patient is asked to bend their wrist down slowly. Tendon subluxation can be detected during this examination.

Table 1 Demographic distribution and intraoperative pathology.

	Group 1: SR	Group 2: ERR	P-value
Mean age (years)	51.75	49.25	0.422
Sex			
Female	11 (91.67%)	10 (83.33%)	0.537
Male	1 (8.33%)	2 (16.67%)	0.537
Subcompartmental	2 (16.67%)	6 (50%)	0.083
Ganglion cyst	1 (8.33%)	1 (8.33%)	1

SR, simple release; ERR, extensor retinaculum reconstruction

Table 2 Preoperative and Postoperative Scores.

Functional scores	Group 1: SR	Group 2: ERR	P-value
Preoperative VAS	7.83	8.17	0.887
Preoperative DASH	61.44	66.52	0.59
Postoperative VAS	2.17	2.67	0.843
Postoperative DASH	15.47	16.33	0.63

SR, simple release; ERR, extensor retinaculum reconstruction; VAS, visual analog scale; DASH, Disabilities of the Arm, Shoulder and Hand

Table 3 Prevalence of complications between Groups 1 and 2.

Complication	Group 1: SR	Group 2: ERR	P-value
Tendon subluxation	2 (16.67%)	0	0.14
Infection	2 (16.67%)	1 (8.33%)	0.537
Nerve injury	1 (8.33%)	2 (16.67%)	0.537

SR, simple release; ERR, extensor retinaculum reconstruction

RESULTS

This study included 26 patients, two of whom were lost to follow-up. Consequently, each group had 12 patients available for follow-up of the treatment outcomes. In Group 1, the mean age was 51.75 years, whereas in Group 2, it was 49.25 years. The sex distribution of the study participants included three males and 21 females, with 62.5% of cases affecting the dominant wrist. Intraoperatively, subcompartments separating the abductor pollicis longus and extensor pollicis brevis were identified in 33.33% of the cases (eight patients), with two patients in Group 1 and six in Group 2. Intratendinous ganglion cysts were observed in 8.33% of the cases (two patients), with one patient in each group, as detailed in Table 1. The mean preoperative VAS and DASH scores for Group 1 were 7.83 and 61.44, respectively, and those for Group 2 were 8.17 and 66.52, respectively ($p = 0.887$ and 0.59, respectively). Three months postopera-

tively, the VAS and DASH scores for Group 1 changed to 2.17 and 15.47, respectively, whereas those for Group 2 changed to 2.67 and 16.33, respectively ($p = 0.843$ and 0.63 , respectively) (Table 2). Complications, including tendon subluxation, were observed in two patients in Group 1, with none in Group 2 ($p = 0.14$). All infections were superficial, with two cases in Group 1 and one case in Group 2, and were managed with oral antibiotics for 1–2 weeks. All nerve injuries were neurapraxic and were found in one and two patients in Groups 1 and 2, respectively. The additional complications are detailed in Table 3.

DISCUSSION

De Quervain's tenosynovitis is a common disease that often results from excessive wrist use. When non-operative treatments prove ineffective, surgery is the next viable option. The initial surgery introduced by Dr. Fritz De Quervain⁽⁸⁾ involved a transverse incision⁽⁹⁾, which was later associated with an increased risk of superficial radial nerve injury. Subsequently, a longitudinal incision was proposed⁽¹⁰⁾, proving to be a safer approach with favorable treatment outcomes. Other alternatives, such as a lazy S or oblique incision⁽¹¹⁾, have also been explored. A comparative study of longitudinal and transverse incisions revealed a higher likelihood of hypertrophic scarring and superficial radial nerve injury with transverse incisions. For this study, an oblique incision was selected because it demonstrated no nerve injury and resulted in the absence of hypertrophic scars⁽¹²⁾.

The pain and functional outcomes in this study were not significantly different between the two surgery types. Tendon subluxation, a common complication associated with substantial functional impairment and potential nerve injury on the volar and dorsal sides⁽¹³⁾, can lead to wrist pain. To address this issue, various surgical methods have been devised, including brachioradialis flap⁽¹⁴⁾ and ERR. Different techniques, as described by many authors⁽¹⁵⁻¹⁷⁾, aim to correct tendon subluxations. The Bakhach method involves cutting the periosteal area in front of the radial styloid into an omega shape, creating additional space for tendon movement without disturbing the pulley. Van de

Wijk's approach includes a diagonal cut to the pulley, a cut to the base of the bone, suturing, space enhancement, and prevention of tendon subluxation. In this study, Takagi's method was used, employing step-cut and restoration sutures. Two cases of tendon subluxation occurred in the SR group, whereas none were reported in the ERR group; however, the difference was not statistically significant.

The primary limitation of this study is its relatively small sample size. Future research should include a larger number of patients to enhance the statistical power of this study. Additionally, the various types of tendon reconstruction surgeries were not compared in this study. Focusing solely on short-term results may not provide a comprehensive understanding of the longevity of complications, suggesting the need for further investigation with extended follow-up periods.

CONCLUSIONS

Surgery for De Quervain's tenosynovitis, whether through SR or ERR, has proven to be effective. However, the likelihood of postoperative pain and tendon subluxation was higher in the SR group.

REFERENCES

1. Ilyas AM, Ast M, Schaffer AA, Thoder J. De quervain tenosynovitis of the wrist. *J Am Acad Orthop Surg* 2007;15:757-64.
2. Altay MA, Erturk C, Isikan UE. De Quervain's disease treatment using partial resection of the extensor retinaculum: A short-term results survey. *Orthop Traumatol Surg Res* 2011;97:489-93.
3. Abrisham SJ, Karbasi MH, Zare J, et al. De quervian tenosynovitis: clinical outcomes of surgical treatment with longitudinal and transverse incision. *Oman Med J* 2011;26:91-3.
4. Belsole RJ. De Quervain's tenosynovitis diagnostic and operative complications. *Orthopedics* 1981;4:899-903.
5. El Rassi G, Bleton R, Laporte D. Compartmental reconstruction for de Quervain stenosing

- tenosynovitis. *Scand J Plast Reconstr Surg Hand Surg* 2006;40:46-8.
6. White GM, Weiland AJ. Symptomatic palmar tendon subluxation after surgical release for de Quervain's disease: a case report. *J Hand Surg Am* 1984;9:704-6.
 7. Kim JH, Yang SW, Ham HJ, et al. Tendon subluxation after surgical release of the first dorsal compartment in de Quervain disease. *Ann Plast Surg* 2019;82:628-35.
 8. de Quervain F. On a form of chronic tendovaginitis by Dr. Fritz de Quervain in la Chaux-de-Fonds. 1895. *Am J Orthop (Belle Mead NJ)* 1997;26:641-4.
 9. Le Viet D, Lantieri L. De Quervain's tenosynovitis. Transversal scar and fixation of the capsular flap. *Rev Chir Orthop Reparatrice Appar Mot* 1992;78:101-6.
 10. Bruner JM. Optimum skin incisions for the surgical relief of stenosing tenosynovitis in the hand. *Plast Reconstr Surg* 1966;38:197-201.
 11. Poublon AR, Kleinrensink GJ, Kerver A, et al. Optimal surgical approach for the treatment of Quervain's disease: A surgical-anatomical study. *World J Orthop* 2018;9:7-13.
 12. Kumar K. Outcome of longitudinal versus transverse incision in de Quervain's disease and its implications in Indian population. *Musculoskelet Surg* 2016;100:49-52.
 13. Collins ED. Radial ridge excision for symptomatic volar tendon subluxation following de Quervain's release. *Tech Hand Up Extrem Surg* 2014;18:143-5.
 14. McMahon M, Craig SM, Posner MA. Tendon subluxation after de Quervain's release: treatment by brachioradialis tendon flap. *J Hand Surg Am* 1991;16:30-2.
 15. Takagi T, Kobayashi Y, Watanabe M. Extensor retinaculum reconstruction using the wide-awake approach. *J Hand Surg Am* 2017;42:844.e1-4.
 16. Bakhach J, Sentucq-Rigal J, Mouton P, et al. The Omega "Omega" pulley plasty: a new technique for the surgical management of the De Quervain's disease]. *Ann Chir Plast Esthet* 2006; 51:67-73.
 17. van der Wijk J, Goubau JF, Mermuys K, et al. Pulley reconstruction as part of the surgical treatment for de Quervain disease: Surgical technique with medium-term results. *J Wrist Surg* 2015;4:200-6.