



## Surgical Management and Clinical Outcomes of Spinal Tuberculosis: A Systematic Review and Meta-analysis on Current Concepts and Strategies

Daniel Encarnacion-Santos, MD<sup>1</sup>, Gennady Chmutin, MD<sup>1</sup>, Egor Chmutin, MD<sup>1</sup>,  
Ariel Tapia Sierra, MD<sup>3</sup>, Shahboz Boboev Ibromovich, MD<sup>2</sup>, Emmanuel Batista-Geraldino, MD<sup>4</sup>,  
Adam Mainer Romanovish, MD<sup>1</sup>, Peter Magembe, MD<sup>5</sup>

<sup>1</sup> Department of Neurosurgery, Federal State Autonomous Educational Institution of Higher Education, "Peoples' Friendship" University, Moscow, Russia

<sup>2</sup> Department of Nervous Diseases and Neurosurgery of the Medical Institute, FSAOU IN RUDN

<sup>3</sup> Department of Traumatology and Orthopedic, University Teaching Hospital, Dr. Dario Contreras, Santo Domingo, Este, Dominican Republic

<sup>4</sup> Department of Neurosurgery, University teaching Hospital, Juan Pablo Pina, San Cristóbal, Dominican Republic

<sup>5</sup> Department of Orthopedics and Spine Surgery, Kilimanjaro Christian Medical Centre Hospital, Kilimanjaro, Tanzania

**Background:** Spinal tuberculosis, also known as Pott's disease, accounts for nearly half of all musculoskeletal tuberculosis cases and is the most common form in children and young adults. Its incidence is increasing in developed countries. This study aimed to evaluate surgical outcomes, from percutaneous biopsy to anterior and posterior spinal decompression, in patients with spinal tuberculosis and kyphosis through different surgical procedures and the expectation of clinical outcomes.

**Methods:** A comprehensive search was conducted across ScienceDirect, PubMed/MEDLINE, and Google Scholar in accordance with the PRISMA guidelines. Statistical analysis was performed using R statistical software and Excel (PROSPERO REGISTRATION NUMBER: CRD420261327294). The search terms included "spinal tuberculosis" and its management, surgical techniques, and associated outcomes related to morbidity and mortality, as well as related pathologies. Inclusion criteria were limited to English-language studies published between January 2012 and September 2025.

**Results:** In this review, a total of 2,710 patients with spinal tuberculosis were identified. Of these, 1,010 patients (37%) were analyzed for surgical approach; 439 (16%) underwent a posterior approach, and 554 (20%) underwent an anterior approach. Regarding diagnostic methods, among 1,700 patients (63%), 867 (32%) underwent histopathological examination, 1,211 (44%) had smear testing, and 858 (31%) were tested using GeneXpert.

**Conclusions:** Spinal tuberculosis remains complex in both diagnosis and surgical management. Well-executed anterior or posterior approaches are effective for kyphosis correction and spinal cord decompression. However, biopsy performed post-laminectomy through paravertebral or multifidus muscle incisions carries a higher risk of sample contamination compared with alternative techniques.

**Keywords:** Spinal tuberculosis, anterior approach, posterior approach, laminectomy, decompression, spinal fusion and clinical outcomes, Pott's disease

*Article history:**Received: March 2, 2026 Revised: May 16, 2026**Accepted: May 28, 2026**Correspondence to: Daniel Encarnacion-Santos, MD**Department of Neurosurgery, Federal State Autonomous Educational Institution of Higher Education, "Peoples' Friendship" University, Moscow, Russia**E-mail: Danielenencarnacion2280@gmail.com***INTRODUCTION**

Spinal tuberculosis (STB) is a severe form of extrapulmonary tuberculosis (TB), accounting for nearly half of all musculoskeletal TB cases. It is the most common form in children and young adults, with a high incidence in developing countries and a significant resurgence in developed nations. Genetic susceptibility has also been identified in STB. Recognized as one of the oldest diseases—with evidence dating back to Egypt in 3,400 BC—it is commonly referred to as Pott's disease and may lead to Pott's paraplegia. Sir Percival Pott first described this spinal infection in 1779, primarily observing its effects in pediatric patients (Garg and Somvanshi, 2011). TB remains prevalent in developing countries and is characterized by cold abscess formation, which may result in mass effect, neurological deficits, or kyphotic deformity of the spine due to destruction of the anterior vertebral bodies. Estimates suggest that at least 10% of patients with extrapulmonary TB have skeletal involvement (Khanna and Sabharwal, 2019). The diagnosis is initially guided by imaging, whereas definitive diagnosis at the tissue level relies on culture, histopathology, and polymerase chain reaction (PCR), the latter considered the gold standard.

The primary treatment strategy involves multidrug chemotherapy to prevent relapse, achieve cure, and minimize residual kyphosis. Surgical treatment includes correction of spinal deformity, stabilization of the spine, and spinal fusion (Schirmer et al., 2010).

Management also includes antituberculosis chemotherapy, which leads to spontaneous fusion in approximately 80% of cases. Surgical

intervention is indicated in cases of vertebral instability, failure of chemotherapy, progressive vertebral deformity, neurological deficits, or epidural abscesses. Surgical management aims to achieve spinal decompression, deformity correction, stabilization, and fusion, often using anterior, posterior, or combined approaches to optimize neurological recovery (Soares Do Brito et al., 2014; Ruparel et al., 2022).

**MATERIALS AND METHODS**

This systematic review was conducted in accordance with the PRISMA guidelines (Preferred Reporting Items for Systematic Reviews and Meta-Analyses). The study focused on postoperative outcomes across various treatment modalities for spinal destructive lesions caused by TB. A comprehensive literature search was performed across multiple electronic databases, including ScienceDirect, PubMed/MEDLINE, and Google Scholar. The search terms included "spinal tuberculosis" combined with keywords such as "surgical management," "surgical techniques," "morbidity and mortality," and "clinical outcomes." The inclusion criteria were limited to original studies published in English between January 2012 and September 2025. Statistical analysis and data synthesis were performed using R statistical software and Microsoft Excel. This review was registered with **PROSPERO (Registration Number: CRD420261327294)**.

The PICO framework (Population, Intervention, Comparison, and Outcome) was used to define the study population, which consisted of patients aged 18 to 75 years with STB. The interventions included anterior, posterior, and anterolateral approaches. Comparisons were made among these surgical approaches, and the outcomes assessed included postoperative outcomes related to the treatment and management of STB.

**Search Strategy and MeSH Terms**

("Tuberculosis, Spinal/blood"[Mesh] OR "Tuberculosis, Spinal/cerebrospinal fluid"[Mesh] OR "Tuberculosis, Spinal/classification"[Mesh] OR "Tuberculosis, Spinal/complications"[Mesh] OR "Tuberculosis, Spinal/congenital"[Mesh] OR

"Tuberculosis, Spinal/diagnosis"[Mesh] OR  
 "Tuberculosis, Spinal/diagnostic imaging"[Mesh]  
 OR "Tuberculosis, Spinal/diet therapy"[Mesh] OR  
 "Tuberculosis, Spinal/drug therapy"[Mesh] OR  
 "Tuberculosis, Spinal/embryology"[Mesh] OR  
 "Tuberculosis, Spinal/epidemiology"[Mesh] OR  
 "Tuberculosis, Spinal/genetics"[Mesh] OR  
 "Tuberculosis, Spinal/immunology"[Mesh] OR  
 "Tuberculosis, Spinal/metabolism"[Mesh] OR  
 "Tuberculosis, Spinal/mortality"[Mesh] OR  
 "Tuberculosis, Spinal/pathology"[Mesh] OR  
 "Tuberculosis, Spinal/physiopathology"[Mesh] OR  
 "Tuberculosis, Spinal/prevention and  
 control"[Mesh] OR "Tuberculosis,  
 Spinal/radiotherapy"[Mesh] OR "Tuberculosis,  
 Spinal/rehabilitation"[Mesh] OR "Tuberculosis,  
 Spinal/surgery"[Mesh] OR "Tuberculosis,  
 Spinal/therapy"[Mesh]

Additional keywords included  
 "tuberculosis of the spine," "tuberculosis  
 paraplegia," "spondylodiscitis," "anterior  
 approach," "posterior approach," "Pott's disease,"  
 "abscess," "lumbar lesions," "thoracic lesions," and  
 "cervical lesions."

### ***Inclusion Criteria***

Patients aged 18 to 75 years with spinal fractures caused by STB, spinal instability, or progressive spinal deformity due to destruction of the vertebral bodies and who were candidates for surgical stabilization, decompression, or fusion were included. Diagnosis was confirmed using magnetic resonance imaging (MRI) to determine the affected spinal level, with or without abscess formation. The diagnosis was further confirmed using gold-standard microbiological methods, including PCR or culture for TB.

### ***Exclusion Criteria***

Patients with non-tuberculous spinal abscesses, pediatric patients with non-tuberculous conditions, and patients with spinal metastases without evidence of TB were excluded.

### ***Data Collection***

Data were managed using the Rayyan intelligent system. The selected studies covered

various aspects of STB, including diagnosis, PCR of swabs, GeneXpert, culture methods, management, and treatment. Extracted study information included the research title, first author, publication date, country, and baseline characteristics of study participants. Study design and sample size were recorded, and demographic variables such as age and sex, as well as intervention measures, were considered. Factors influencing subdural, epidural, and spinal hemorrhages were evaluated, including spinal cord involvement, spinal canal compromise, and debridement. Conservative and surgical treatments were determined according to the Frankel scale for neurological deficits resulting from deformity, abscess formation, and instability. Surgical techniques were also thoroughly reviewed because of their associated morbidity and mortality rates, particularly in comparison with survival outcomes in patients with spinal cord injuries and fractures secondary to STB.

### ***Data Extraction and Analysis***

Data were extracted using a standardized protocol from relevant research manuscripts identified in PubMed/MEDLINE. Comprehensive study details were collected, including demographic characteristics, interventions, comparator parameters in comparative studies, authorship, year of publication, and study design. The data analysis plan was predefined before data collection. Statistical analysis was conducted using R software and Microsoft Excel. The search strategy investigated all clinical aspects of spinal injuries secondary to TB. A forest plot was generated to assess heterogeneity and calculate p-values to identify patterns of vertebral body destruction and the severity of STB-related injuries.

### ***Risk of Bias Assessment***

Two independent reviewers used the ROBINS-I (Risk of Bias in Non-randomized Studies of Interventions) tool to evaluate the methodological quality of 14 included studies. Each study was categorized as having a low, moderate, or high risk of bias across predefined domains. The assessment considered potential biases related to patient selection, intervention classification, and

outcome measurement. Furthermore, the applicability of each study was evaluated based on clinical relevance, including diagnostic methods for TB, surgical approaches (anterior vs. posterior), and postoperative outcomes.

### Statistical Analysis

All statistical analyses were performed using Review Manager (RevMan) version 5.4.1 and Microsoft Excel. Quantitative data were presented as mean  $\pm$  standard deviation. Comparative analyses were conducted based on the affected spinal levels (sacral, lumbar, thoracic, or cervical), with the thoracolumbar region being the most frequently affected. The heterogeneity of treatment effects and outcomes across studies was assessed. A fixed-effects model was applied when no significant heterogeneity was observed ( $P > 0.05$ ); otherwise, a random-effects model was used. Therefore, the random-effects model was adopted when significant heterogeneity was present. When statistical heterogeneity was detected among study outcomes, its sources were further explored. After accounting for clinical heterogeneity, subgroup analyses (A and B) and sensitivity analyses were performed to address the remaining heterogeneity. Significant differences were observed between the two groups ( $P < 0.05$ ). Regarding effect measures, mean differences and likelihood ratios were calculated for the outcomes of interest. Finally, a random-effects model was used to estimate pooled outcome measures; the inclusion of 14 studies strengthened the meta-analysis.

## RESULTS

A total of 2,710 patients with STB were identified across the included studies. Of these, 1,010 patients (37%) were evaluated for surgical interventions (Table 1). Specifically, 439 patients (16%) underwent a posterior approach, whereas 554 (20%) were treated using an anterior approach (Figures 1–2). Regarding diagnostic modalities, among 1,700 patients (63%) analyzed (Table 2), 867 (32%) underwent histopathological examination, 1,211 (44%) were tested using smear microscopy, and 858 (31%) were diagnosed using GeneXpert (Figures 3–6). Meta-analysis of Surgical

Approaches Comparative analysis between anterior–posterior and posterolateral approaches revealed a statistically significant difference in clinical outcomes. The OR was 0.69 (95% confidence interval [CI]: 0.49–0.96;  $I^2 = 37\%$ ;  $Z = 2.21$ ;  $P = 0.03$ ). Similarly, the risk ratio (RR) was 0.84 (95% CI: 0.77–0.98;  $I^2 = 37\%$ ;  $Z = 2.21$ ;  $P = 0.03$ ). The risk difference (RD) also demonstrated a significant overall effect ( $I^2 = 37\%$ ;  $Z = 2.25$ ;  $P = 0.02$ ). In the subgroup analysis comparing Group A and Group B, no statistically significant differences were observed. The OR for heterogeneity was 1.16 (95% CI: 0.88–1.51;  $I^2 = 74\%$ ;  $Z = 1.05$ ;  $P = 0.29$ ). The RR was 1.08 (95% CI: 0.94–1.24;  $I^2 = 74\%$ ;  $Z = 1.05$ ;  $P = 0.29$ ), and the RD was 0.04 (95% CI: 0.03–0.10;  $I^2 = 74\%$ ;  $Z = 1.07$ ;  $P = 0.28$ ).

### Pathological Investigation

The evaluation of vertebral pathological lesions integrates laboratory testing and diagnostic imaging to identify the causative agent of TB infection. Diagnostic samples are frequently obtained via percutaneous needle biopsy or intraoperative open biopsy; both methods are recognized as accurate, essential, and effective for rapid diagnosis (Guha et al., 2021). In cases where lesions are confined to the vertebrae and resemble noncontiguous STB, percutaneous needle biopsy offers distinct advantages over open biopsy. Microbiological assessments, including PCR and histological staining, are performed. STB is categorized into three pathological types: exudative, hyperplastic, and necrotic, which correlate with varying levels of bacterial virulence and host immune response (Li et al., 2020). These pathological features often coexist and interact in various combinations depending on the stage of disease progression (Khanna and Sabharwal, 2019). Although classic histological findings include granuloma formation, caseous necrosis, lymphocytic infiltration, and multinucleated giant cells, atypical clinical manifestations can sometimes hinder the diagnosis of STB. Some studies have reported a spectrum of changes ranging from acute inflammatory or exudative alterations to chronic proliferative changes (Na et al., 2023).

**Table 1** Patients with spinal tuberculosis undergoing anterior and posterior approaches, including debridement, decompression with laminectomy and instrumentation, autografting, and fixation.

Author	Year	Study design	Patients (n)	Posterior approach A (n)	Anterior approach B (n)	Technique group A	Technique group B	Follow-up	P value
Pu X. et al.	2012	Comparative study	47	25	22	Debridement, interbody autografting, and instrumentation	Debridement, interbody autografting, and instrumentation	12–62 months	P > 0.05
Yuliang D. et al.	2017	Comparative study	90	38	53	Anterior debridement, bone grafting, and instrumentation via the VATS approach	Posterior-only approach	5 years	N/A
Li W. et al.	2019	Retrospective study	87	39	48	Anterior transthoracic debridement and fusion	Posterior transpedicular debridement and fusion	5–10 years	P < 0.05
Musali S.R. et al.	2023	Retrospective study	30	15	15	Anterolateral decompression and spinal stabilization	Posterolateral decompression via costotransversectomy and spinal stabilization	12 months	N/A
Zhao C. et al.	2020	Retrospective study	30	19	16	Kyphosis correction and angle measurement	Kyphosis correction and angle measurement	2 years	P < 0.05
Jiang L. et al.	2022	Retrospective study	67	31	36	Decompression and debridement via the paraspinous abscess side	Resection to decompress the spinal cord and debride the lesion	3 years	P < 0.01
Qiu J. et al.	2022	Retrospective study	52	28	24	Complete debridement	Complete debridement with adequate anterior spinal cord decompression	27 months	P > 0.05
Wu H. et al.	2021	Retrospective study	87	40	47	Debridement, interbody fusion, and fixation	Single posterior approach	34.3 ± 9.5 months (24–56 months)	P > 0.05
Garg B. et al.	2012	Retrospective study	70	34	36	Anterior transthoracic debridement, decompression, and instrumentation	Posterolateral (extracavitary) decompression and posterior instrumentation	26 months.	P > 0.05
Shi J. et al.	2014	Retrospective study	148	78	48	Anterior debridement and bone graft fusion with screw-based internal fixation	Posterior debridement, bone graft fusion, and pedicle-based internal fixation	N/A	P < 0.01
Wang X. et al.	2013	Clinical trial	115	55	60	One-stage anterior debridement, bone grafting, and posterior instrumentation	Single posterior debridement, bone grafting, and instrumentation	12–36 months (mean 21.3 months)	P > 0.05
Huang Y. et al.	2017	Retrospective study	187	37	149	Debridement, joint bone grafting, and internal fixation	Posterior debridement, joint bone grafting, and internal fixation	12.0 ± 18.4 months	P > 0.05

**Table 2** Patients with spinal tuberculosis evaluated by acid-fast bacilli smear, culture, histopathology, and GeneXpert, including sensitivity and specificity.

Author	Study Design	Year	Patients (n)	Culture (n)	Smear (n)	GeneXpert (n)	Sensitivity (%)	Specificity (%)	Followup	P value
Wang G. et al.	Prospective head-to-head cohort study	2018	319	139	60	163			18 months	P < 0.001
Shetty A. et al.	Retrospective study	2022	150	40	101	108	100%	80%	N/A	N/A
Jagiasi Dr JD. et al.	Retrospective study	2020	31	21	12	24	77%	N/A	2 years	N/A
Massi M.N. et al.	Retrospective study	2017	70	62	22	22	100%	16.6%	N/A	N/A
Arockiaraj J. et al.	Retrospective study	2017	254	204	348	225	100%	71%	24 months	N/A
Karthek V. et al.	Retrospective study	2021	125	45	136	125	65.1%	100%	N/A	N/A
Qi Y. et al.	Retrospective study	2022	203	85	110	56	78.18%	76.56%	N/A	P < 0.001
Zhou Z. et al.	Retrospective study	2021	242	29	84	16	73%	100%	N/A	P < 0.05
Yu Y. et al.	Controlled trial	2020	128	33	106	27	86.7%	97.8%	N/A	P < 0.001
Li Z. et al.	Retrospective study	2023	41	87	126	30	100%	82.4%	N/A	N/A
Held M. et al.	Prospective clinical study	2014	69	69	71	N/A	95.6%	96.2%	N/A	N/A
Solanki A.M et al.	Prospective matched cohort study	N/A	68	53	35	62	88.33%	91.18%	N/A	N/A

### **Mini-open Tubular Retractor System and Posterolateral Decompression**

This technique involves endoscopic debridement through a posterolateral approach with irrigation for the treatment of tuberculous spondylodiscitis (Encarnación-Santos et al., 2024). Percutaneous instrumentation using pedicle screws enables stabilization of the thoracic and lumbar spine. Decompression of the spinal cord or thecal sac can be achieved similarly to facetectomy using a retractor system or via interbody fusion performed through a transforaminal or direct lateral approach (Encarnacion Santos et al., 2024). Furthermore, favorable outcomes have been reported with multisegmental percutaneous instrumentation for managing spinal instability in patients with TB (Santos et al., 2024).

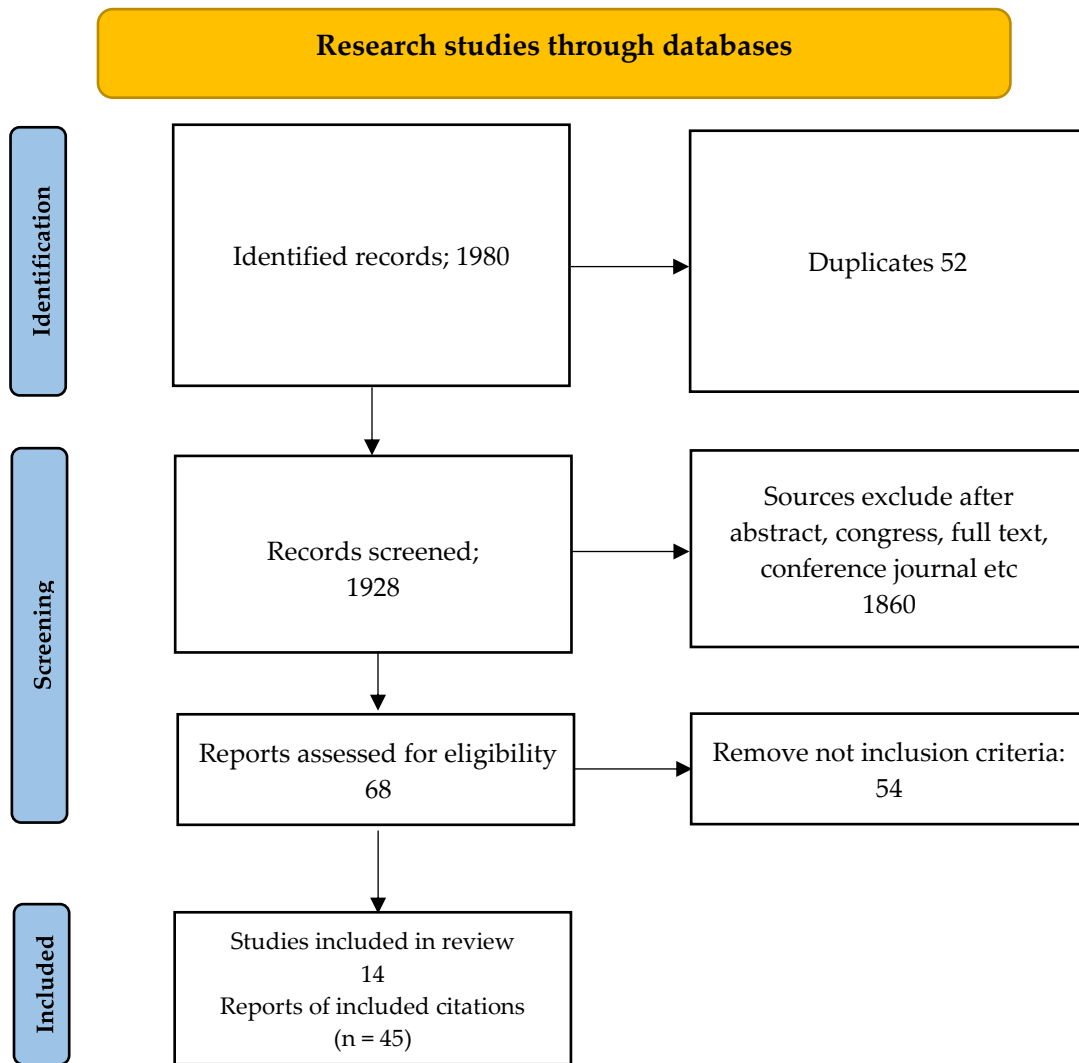
### **Management of Blood Loss in STB**

Surgical management of STB via the anterior approach is often associated with significant intraoperative blood loss. Preoperative anemia is frequently present and must be carefully assessed and managed (Qureshi et al., 2017). To minimize blood loss, patients should be positioned optimally to reduce venous pressure. The administration of antifibrinolytic agents, such as tranexamic acid (TXA) or epsilon-aminocaproic acid (EACA), is strongly recommended (Degoute, 2007). The use of fibrinogen concentrates and thromboelastometry-guided therapy, alongside acute normovolemic hemodilution, controlled hypotension, and core temperature regulation, represents essential blood-conservation strategies (Jamaliya et al., 2014; Ruku et al., 2019). Controlled

hypotension can be achieved using a combination of volatile anesthetics (sevoflurane or isoflurane) with opioids, alpha-blockers, beta-blockers, or sodium nitroprusside. Dexmedetomidine has been shown to be more effective than nitroglycerin in maintaining stable hypotension in adults undergoing spinal surgery with posterior fixation (Ghodraty, 2014; Nazir et al., 2016). Additionally, magnesium sulfate and remifentanyl demonstrate similar efficacy with minimal adverse effects. Hemostatic agents, including recombinant factor VIIa, desmopressin, aprotinin, TXA, and EACA, may also be considered to reduce transfusion

requirements (Hwang and Kim, 2014; Crescenzi et al., 2008).

TXA demonstrates superior efficacy compared with other antifibrinolytic agents by significantly reducing surgical blood loss without increasing the risk of thromboembolism. Postoperatively, the use of fibrin sealants, erythropoietin, and intravenous iron may further reduce blood loss, particularly in patients who refuse blood products (Li et al., 2017; Theusinger and Spahn, 2016). Ultimately, effective blood conservation in complex spinal surgery requires a coordinated multidisciplinary approach (Chilkoti et al., 2020).



**Fig. 1** PRISMA on Spinal tuberculosis (TB).

### Surgical management of Spinal TB

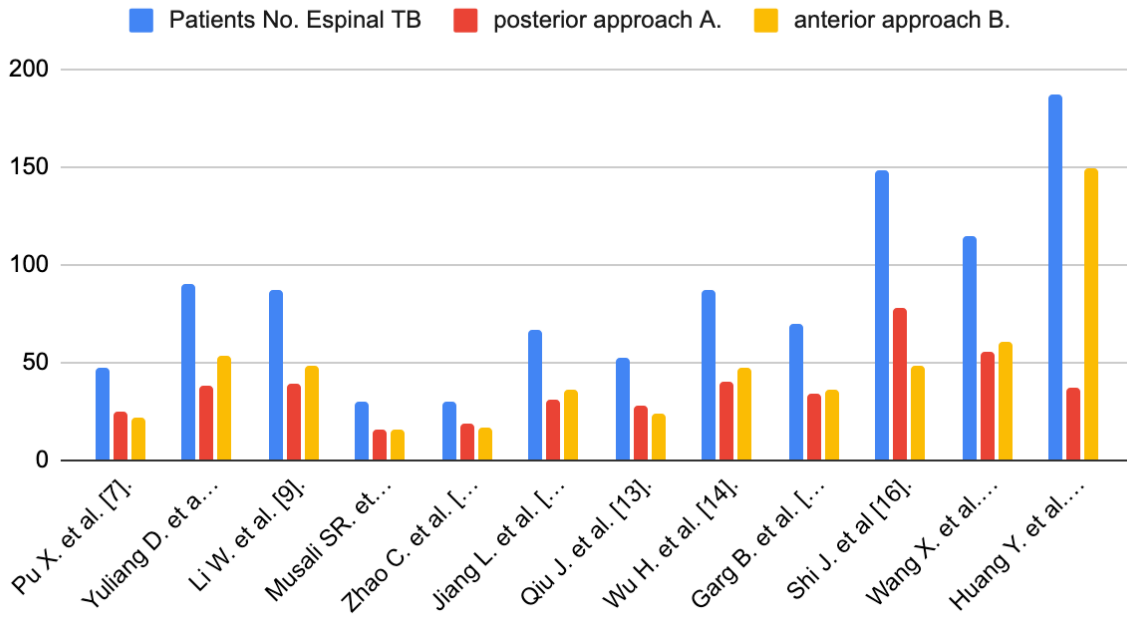


Fig. 2 Patients with spinal TB with anterior and posterior approach.

### Spinal TB culture and Gene Xpert

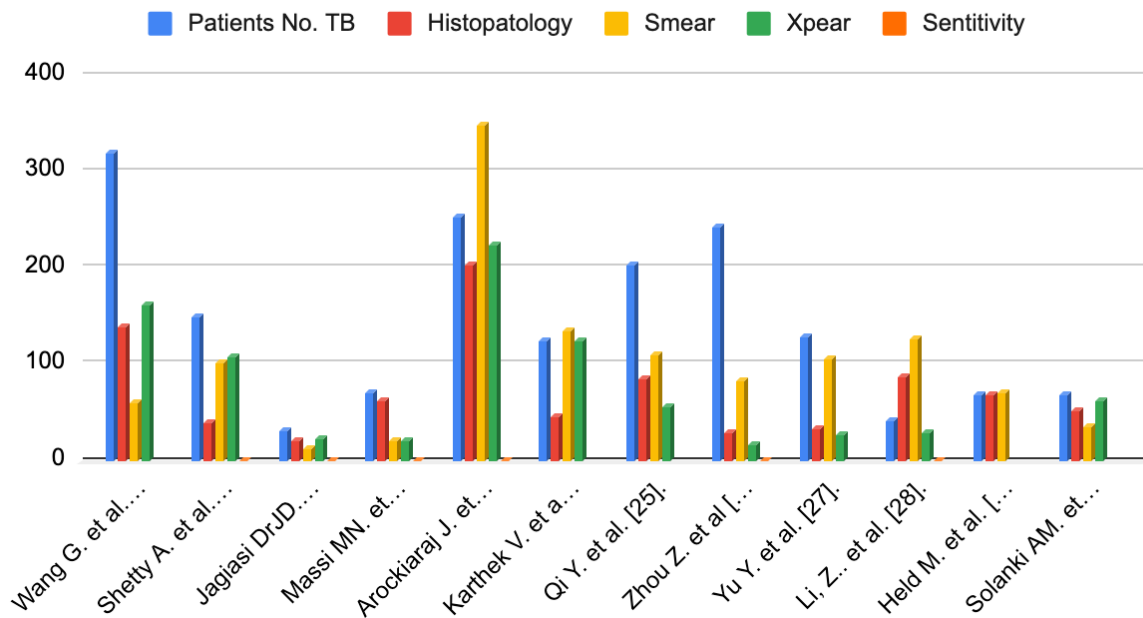
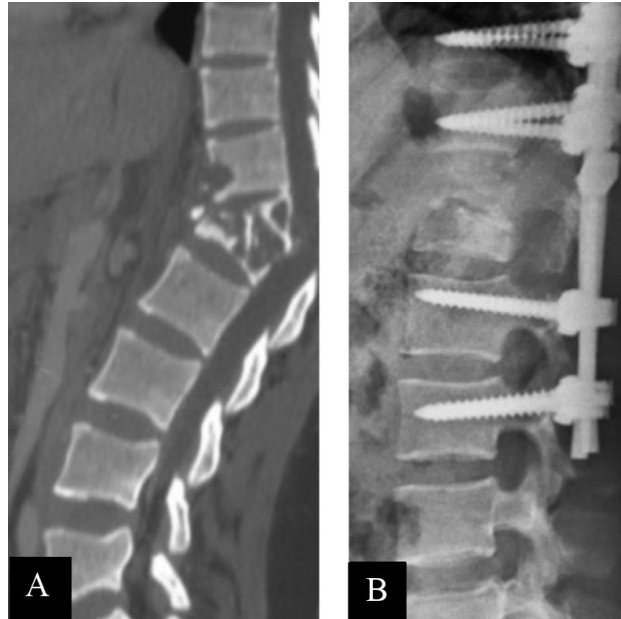


Fig. 3 Patients with Spinal Tuberculosis, acid-fast bacilli, culture and histopathology.



**Fig. 4** A) Preoperative imaging of T12-L1 fracture with spondylodiscitis B) After Decompression, fixation and stabilization with debridement of the thoraco-lumbar.

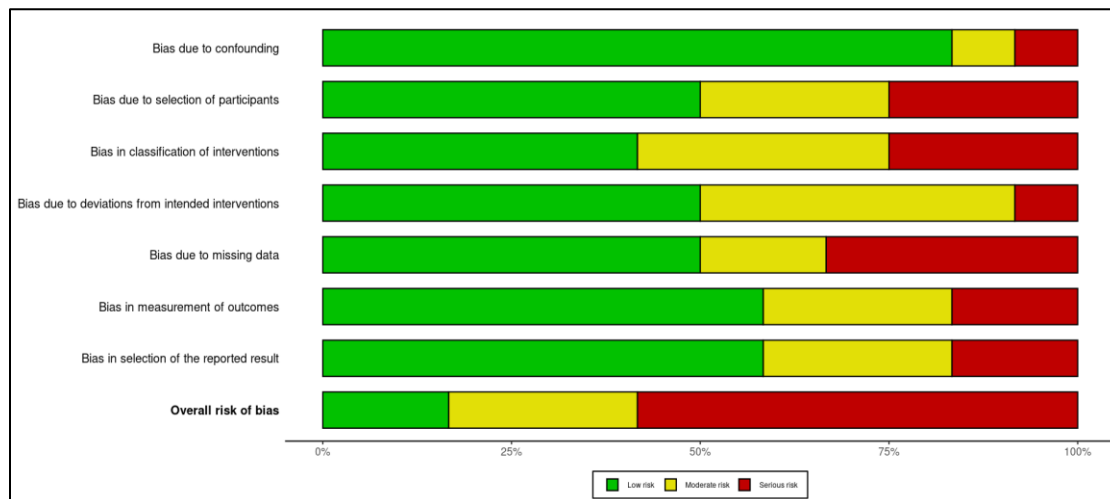
Study	Risk of bias domains							Overall
	D1	D2	D3	D4	D5	D6	D7	
Pu X. et al. [7]	Low	Moderate	Serious	Low	Moderate	Moderate	Serious	Serious
Yufang D. et al. [8]	Low	Low	Moderate	Moderate	Low	Serious	Low	Low
Li W. et al. [9]	Low	Low	Moderate	Low	Moderate	Low	Low	Moderate
Musali SR, et al. [10]	Low	Low	Low	Moderate	Moderate	Low	Moderate	Serious
Zhao C. et al. [11]	Low	Serious	Low	Moderate	Serious	Moderate	Low	Serious
Jiang L. et al. [12]	Low	Low	Serious	Moderate	Low	Low	Serious	Moderate
Qiu J. et al. [13]	Low	Serious	Low	Low	Low	Moderate	Low	Serious
Wu H. et al. [14]	Moderate	Low	Low	Moderate	Serious	Serious	Low	Moderate
Gang B. et al. [15]	Serious	Low	Moderate	Low	Moderate	Low	Low	Serious
Shi J. et al. [16]	Low	Moderate	Low	Serious	Low	Low	Moderate	Serious
Wang X. et al. [17]	Low	Moderate	Serious	Low	Serious	Low	Low	Serious
Huang Y. et al. [18]	Low	Serious	Moderate	Low	Low	Low	Moderate	Serious

Domains: D1: Bias due to confounding, D2: Bias due to selection of participants, D3: Bias in classification of interventions, D4: Bias due to deviations from intended interventions, D5: Bias due to missing data, D6: Bias in measurement of outcomes, D7: Bias in selection of the reported result.

Judgement: Serious (Red), Moderate (Yellow), Low (Green)

**Fig. 5** A, B) Graph and representation risk of bias for patients diagnosed with spinal tuberculosis. The analysis of quality for the meta-analysis was assessed using the ROBINS-I tool: A) Traffic light charts with domain-level assessments for each study and outcomes. B) Weighted bar charts showing the distribution of the bias risk assessment for the studies in the bias domain.

A)



B)

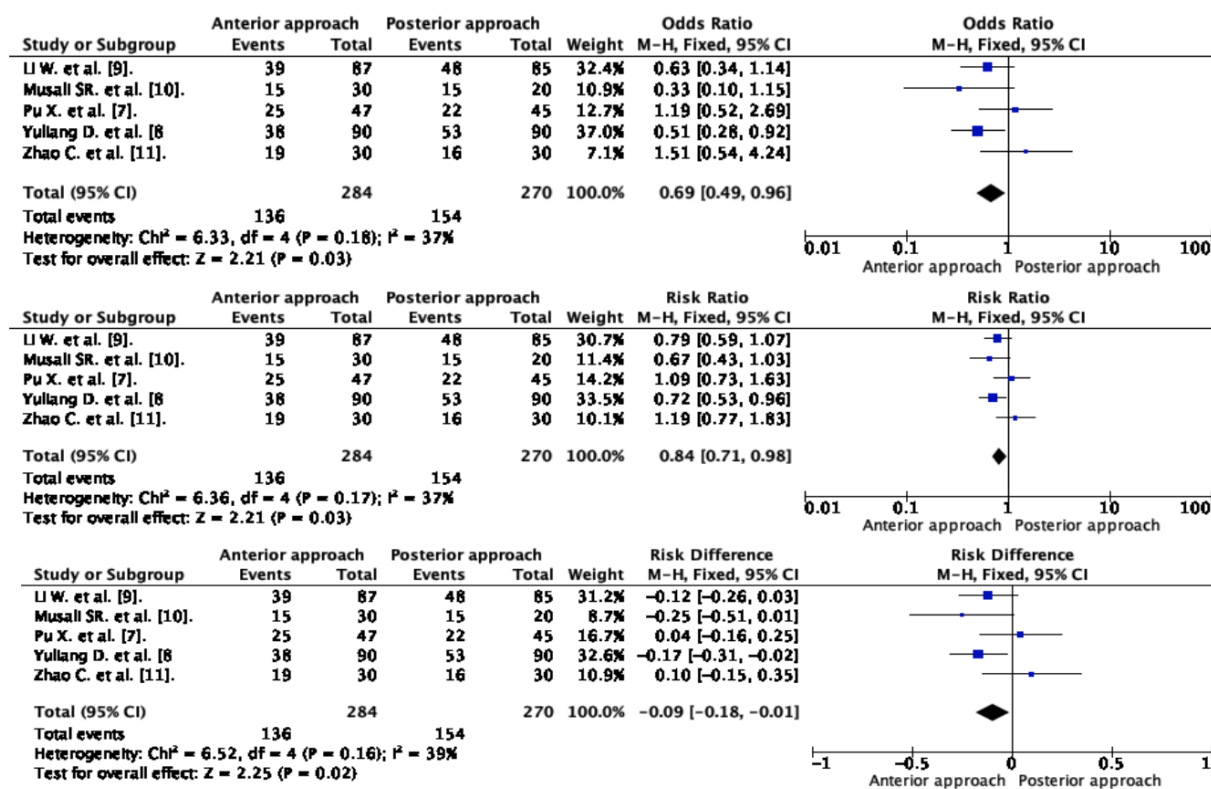


Fig. 6 Forest plot of spinal TB; anterior approach vs. posterior approach.

## DISCUSSION

A retrospective observational study was conducted to evaluate surgical outcomes in patients with STB. The study included 70 patients presenting with extrapulmonary TB and significant spinal involvement. Patients were classified and analyzed according to the American Spinal Injury Association (ASIA) Impairment Scale. All patients underwent laminectomy and epidural drainage for abscesses, along with transpedicular debridement of granulation tissue, with or without spinal stabilization. The thoracolumbar region was treated using a posterior approach. Notably, 12 patients presented with spinal cord compression involving the facet joints; these individuals required fusion and minimally invasive spine surgery (MISS) fixation using pedicle screws. Cervical involvement was managed using an anterior approach. The thoracic region was the most frequently affected site ( $n = 28$ ), followed by the lumbar ( $n = 20$ ), cervical ( $n = 16$ ), and thoracolumbar regions ( $n = 6$ ). Epidural abscesses were identified in 20 patients.

All patients treated with antituberculosis therapy according to established guidelines showed clinical improvement within four weeks, with 17 patients with epidural abscesses achieving neurological recovery (classified as ASIA grades B, D, and E), whereas only four patients demonstrated delayed postoperative recovery. Consequently, adherence to the established treatment protocol and MRI follow-up was associated with statistically significant clinical improvement (Srinivasa et al., 2021).

TB remains more prevalent in developing countries; however, it continues to pose a significant global health threat. The rising prevalence of multidrug-resistant tuberculosis is a major concern. STB accounts for approximately 40% of extrapulmonary TB cases. Patients with extensive spinal involvement and vertebral body collapse often present significant clinical challenges; these cases frequently involve large lesions or abscesses that compress the spinal cord. Although conventional treatment for STB typically

spans 6 to 24 months, it remains effective in approximately 80% of cases (Pu et al., 2012).

Yuliang et al. reported that although an anterior approach may facilitate complete recovery with minimal surgical trauma, a posterior approach is often preferred for proximal thoracic spine involvement, particularly in cases with significant kyphotic deformity. Similarly, Li et al. stated that anterior transthoracic debridement and fusion, as well as posterior transpedicular fusion, are associated with a low risk of postoperative complications, making them suitable for patients with mid-thoracic STB at T5–T9. Therefore, the anterior approach may be associated with earlier fusion. In contrast, Musali et al. argued that the posterolateral approach is highly effective for spinal decompression and stabilization. This technique facilitates kyphosis correction, resulting in pain relief and neurological recovery, along with a shorter hospital stay and reduced morbidity (Yuliang et al., 2017; Li et al., 2019; Musali et al., 2023).

Wang et al. demonstrated that modern molecular diagnostic tests significantly improve diagnostic accuracy in STB, thereby increasing the proportion of confirmed cases and reducing treatment delays. Consequently, the implementation of an updated diagnostic algorithm may ensure broader availability of these tools. Meanwhile, Shetty et al. emphasized that a single diagnostic technique is often insufficient, necessitating a combined diagnostic approach. Arockiaraj J. et al. recommended the GeneXpert MTB/RIF assay for early detection of *Mycobacterium* TB spondylodiscitis and rapid identification of rifampicin resistance (Wang et al., 2018; Shetty et al., 2022; Arockiaraj et al., 2017).

#### **Risk Factors for STB (Pott's Disease)**

Individuals living with human immunodeficiency virus (HIV) are significantly more susceptible to TB, particularly in high-density environments such as prisons (Dunn and Ben Husien, 2018). The global burden of TB indicates that since 2016, an estimated 9.02 million cases and 1.21 million deaths have been attributed to the disease (Bruchfeld et al., 2015). TB was the third leading cause of death worldwide in 1990 and

ranked fourth in 2017. Geographically, the World Health Organization reported that in 2019, 44% of TB cases occurred in Southeast Asia, 25% in Africa, and 18% in the Western Pacific region (Ding et al., 2022), with more than 20 countries accounting for 84% of the global burden.

HIV infection increases susceptibility to TB coinfection and exacerbates both the severity of clinical manifestations and the progression of HIV to acquired immunodeficiency syndrome, which is primarily characterized by depletion of CD4+ T lymphocytes (Bell and Noursadeghi, 2018). These cells are essential for host immunity against *Mycobacterium tuberculosis*, as they coordinate the function of other T lymphocytes and help prevent immune exhaustion (Lu et al., 2021). Specifically, the T-helper 1 (Th1) subtype of CD4+ T lymphocytes releases interferon-gamma (IFN- $\gamma$ ), a cytokine that activates macrophages and enhances phagocytosis and elimination of TB bacilli. Consequently, depletion of Th1 CD4+ T lymphocytes and the subsequent reduction in IFN- $\gamma$  levels increase the risk of primary infection and reactivation of latent Pott's disease (Latorre et al., 2010). These health disparities are often rooted in poverty and the social stigma associated with TB and HIV coinfection. STB, characterized by caseous necrosis, is more prevalent in patients with vitamin D deficiency. Serum levels of 1,25-dihydroxyvitamin D are significantly reduced in patients diagnosed with STB (Montales et al., 2015).

#### **Anterior Surgery or Anterior Approach**

STB lesions frequently destroy the anterior or middle columns, leading to spinal instability. To maintain spinal integrity, the three-column theory should be considered (Denis, 1983). The anterior approach offers several advantages in addressing these lesions. First, it provides complete exposure to facilitate radical debridement of tuberculous spinal lesions. Second, it significantly improves recovery rates and reduces recurrence. Third, it allows thorough exposure of the dural sac, thereby minimizing the risk of spinal nerve or spinal cord injury. Fourth, it enables the surgeon to perform structural bone grafting or rigid fixation to correct kyphosis and restore spinal stability. Fifth,

debridement and bone grafting with internal fixation can be performed through a single incision, thereby reducing operative time and blood loss (Zhao et al., 2020).

However, anterior surgery involving mediastinal organs may limit surgical exposure and fail to adequately correct deformity, thereby posing a higher risk of complications (Yang et al., 2016). Management of TB in the cervicothoracic region or in cases with severe kyphosis further complicates surgical intervention. Although potential complications may arise, such as recurrent laryngeal nerve palsy, hemothorax, pneumothorax, or hypertrophic scarring, preservation of spinal stability remains a priority. The lumbosacral region is highly susceptible to lesions, often associated with sacral and psoas abscesses (Zhu et al., 2018). Anterior surgery, with its wider surgical field, facilitates radical debridement and anatomical structural grafting. Combined anterior and posterior procedures may shorten operative duration, reduce blood loss, and preserve posterior structures, such as the posterior ligamentous complex (Wu et al., 2020). The risk of pseudoarthrosis remains high in tuberculous spine, and maintenance of deformity correction can be challenging. There is also a risk of titanium hardware displacement or fracture, particularly in long-segment internal fixation constructs (Sun et al., 2019).

Key considerations from the literature include the following. First, when more than three vertebral segments are destroyed, anterior surgery may restrict spinal mobility during deformity correction, thereby increasing the risk of postoperative kyphosis, neurological deficits, and fixation failure (Wu et al., 2018). Second, unilateral anterior instrumentation of already compromised segments can generate asymmetrical biomechanical forces on the spine, leading to instability. Third, when vertebral body destruction is too extensive to permit standard screw placement, spinal biomechanics may be altered, increasing the risk of injury to thoracoabdominal organs, vessels, and nerves (Qureshi et al., 2013).

#### ***Posterior Surgery or Posterior Approach***

STB lesions are typically located in the an-

terior and middle columns of the spine, often involving paravertebral abscesses, fluid collections, and the anterior aspect of the vertebral body. Although anterior surgery was long considered the gold standard, posterior surgery has gained popularity in recent years (Fisahn et al., 2017; May and Pfäfflin, 2002; Gao et al., 2021). This approach, which specifically targets the transverse costal process and pedicle border, has demonstrated satisfactory efficacy in debriding tuberculous lesions and decompressing the spinal cord and nerve roots (Zeng et al., 2012; Luo et al., 2016; Huang et al., 2017). Furthermore, posterior internal fixation systems effectively correct kyphosis and restore spinal stability while minimizing surgical and instrumentation-related complications. This approach offers the advantage of reduced surgical trauma while maintaining a high capacity for deformity correction (Qiu et al., 2022).

Despite these benefits, several limitations must be considered. First, because STB lesions primarily involve the anterior and middle columns, posterior procedures may inadvertently disseminate bacilli into relatively unaffected posterior columns, potentially facilitating the spread of infection (Zhao et al., 2019; Gao et al., 2017). Second, the limited surgical field increases the risk of intraoperative injury to the nerve roots or dural sac and may hinder thorough—debridement and complete exposure of tuberculous lesions—particularly in multisegmental or lumbosacral cases—thereby increasing the likelihood of residual disease and recurrence (Santos et al., 2025). Third, posterior surgery is not suitable for structural bone grafting of the anterior column. Fourth, this approach may compromise posterior spinal stability,—necessitating prolonged segmental fixation at the expense of normal spinal motion (Encarnación-Santos et al., 2025; Encarnacion-Santos et al., 2023). Fifth, the posterior approach may cause iatrogenic injury to the paraspinal muscles, resulting in chronic postoperative low back pain. Despite these limitations, posterior surgery offers several advantages.

1. A single incision allows comprehensive surgical management, including debridement of tuberculous lesions, decompression of the spinal

cord and nerve roots, and correction of deformity through rigid internal fixation and grafting (Encarnación-Santos et al., 2024).

2. This approach reduces the risk of injury to thoracic and abdominal organs, as well as major blood vessels.

3. It minimizes complications associated with improper placement of internal fixation devices.

4. Lesions at the complex cervicothoracic or lumbosacral junctions can be effectively managed using this approach, with favorable clinical outcomes (Zeng et al., 2015; Xu et al., 2021).

### *Limitations and Future Directions*

Current evidence suggests that open biopsy may be associated with increased morbidity; consequently, the literature strongly supports the use of percutaneous needle biopsy. The anterior approach may provide limited exposure of mediastinal structures and may not adequately correct deformity, thereby posing a significant risk of complications. Surgical management is further complicated when TB involves the cervicothoracic region or presents with significant kyphosis. Unilateral anterior instrumentation in segments already compromised by TB can induce asymmetric biomechanical stresses, leading to instability. Furthermore, when vertebral destruction involves more than three segments, anterior deformity correction carries a high risk of postoperative kyphosis, neurological impairment, and fixation failure. The need to extend the fixation construct because of extensive vertebral body destruction may compromise normal spinal mobility. Additionally, the anterior approach carries an increased risk of injury to thoracoabdominal organs, vessels, and nerves. Although TB lesions primarily involve the anterior and middle columns, surgical manipulation may inadvertently disseminate tubercle bacilli into relatively unaffected posterior columns, thereby facilitating the spread of infection.

The posterior approach also presents notable limitations, including a restricted surgical field that may result in inadequate debridement, particularly in complex multisegmental or lumbosacral cases. Such limitations increase the

likelihood of residual lesions and disease recurrence. Moreover, there is a risk of intraoperative injury to the spinal nerve roots or dural sac. Finally, posterior procedures may compromise posterior column stability, necessitating long-term segmental fixation at the expense of spinal mobility, and may cause iatrogenic injury to the paravertebral muscles, leading to chronic postoperative low back pain.

### **CONCLUSIONS**

This meta-analysis demonstrates that despite the complexity of STB, both anterior and posterior approaches are effective for kyphosis correction and neurological decompression. Our findings indicate substantial heterogeneity ( $I^2 = 74\%$ ) among the included studies, reflecting the diversity of surgical strategies employed globally. Although a statistically significant difference in outcomes was observed between anterior and posterior approaches, the choice of technique should be tailored to the specific lesion location and severity of deformity. Percutaneous needle biopsy is strongly advised over open biopsy to minimize the risk of contamination. Furthermore, although MISS offers advantages in postoperative recovery, its limited surgical field suggests that microscopic assistance may be necessary to achieve optimal debridement in tuberculous spondylodiscitis.

### **REFERENCES**

1. Garg RK, Somvanshi DS. Spinal tuberculosis: A review. *J Spinal Cord Med* 2011;34:440-54.
2. Khanna K, Sabharwal S. Spinal tuberculosis: a comprehensive review for the modern spine surgeon. *Spine J* 2019;19:1858-70.
3. Schirmer P, Renault CA, Holodniy M. Is spinal tuberculosis contagious? *Int J Infect Dis* 2010;14:e659-66.
4. Soares Do Brito J, Tirado A, Fernandes P. Surgical treatment of spinal tuberculosis complicated with extensive abscess. *Iowa Orthop J* 2014;34:129-36.
5. Ruparel S, Tanaka M, Mehta R, et al. Surgical management of spinal tuberculosis—the past,

- present, and future. *Diagnostics* (Basel) 2022;12:1307.
6. Srinivasa R, Furtado S, Kunikullaya K, et al. Surgical management of spinal tuberculosis - A retrospective observational study from a Tertiary Care Center in Karnataka. *Asian J Neurosurg* 2021;16:695-700.
  7. Pu X, Zhou Q, He Q, et al. A posterior versus anterior surgical approach in combination with debridement, interbody autografting and instrumentation for thoracic and lumbar tuberculosis. *Int Orthop* 2012;36:307-13.
  8. Yuliang D, Li Y, Wang B, et al. Anterior versus posterior surgery for mono-segmental thoracic spinal tuberculosis: selection of the optimal approach and comparison of outcomes. *Int J Clin Exp Med* 2017;10:10463-71
  9. Li W, Liu Z, Xiao X, et al. Comparison of anterior transthoracic debridement and fusion with posterior transpedicular debridement and fusion in the treatment of mid-thoracic spinal tuberculosis in adults. *BMC Musculoskelet Disord* 2019;20:570.
  10. Musali SR, Karla R, Gollapudi PR, et al. Anterolateral versus posterolateral decompression and spinal stabilization in thoracolumbar Potts spine: A comparative study. *Br J Neurosurg* 2023;37:1028-30.
  11. Zhao C, Luo L, Liu L, et al. Surgical management of consecutive multisegment thoracic and lumbar tuberculosis: Anterior-only approach vs. posterior-only approach. *J Orthop Surg Res* 2020;15:343.
  12. Jiang L, Sheng X, Deng Z et al. A comparative study of one-stage posterior unilateral limited laminectomy vs. bilateral laminectomy debridement and bone grafting fusion combined with internal fixation for the treatment of aged patients with single-segment spinal tuberculosis. *BMC Musculoskelet Disord* 2022;23:619.
  13. Qiu J, Peng Y, Qiu X, et al. Comparison of anterior or posterior approach in surgical treatment of thoracic and lumbar tuberculosis: a retrospective case-control study. *BMC Surg* 2022;22:161.
  14. Wu H, Cui Y, Gong L, et al. Comparison between single anterior and single posterior approaches of debridement interbody fusion and fixation for the treatment of mono-segment lumbar spine tuberculosis. *Arch Orthop Trauma Surg* 2021;142:3643-9
  15. Garg B, Kandwal P, Nagaraja UB, et al. Anterior versus posterior procedure for surgical treatment of thoracolumbar tuberculosis: A retrospective analysis. *Indian J Orthop* 2012;46:165-70.
  16. Shi J, Tang X, Xu Y, et al. Single-stage internal fixation for thoracolumbar spinal tuberculosis using 4 different surgical approaches. *J Spinal Disord Tech* 2014;27:E247-57.
  17. Wang X, Pang X, Wu P, et al. One-stage anterior debridement, bone grafting and posterior instrumentation vs. single posterior debridement, bone grafting, and instrumentation for the treatment of thoracic and lumbar spinal tuberculosis. *Eur Spine J* 2014;23:830-7.
  18. Huang Y, Lin J, Chen X, et al. A posterior versus anterior debridement in combination with bone graft and internal fixation for lumbar and thoracic tuberculosis. *J Orthop Surg Res* 2017;12:150.
  19. Wang G, Dong W, Lan T, et al. Diagnostic accuracy evaluation of the conventional and molecular tests for Spinal Tuberculosis in a cohort, head-to-head study. *Emerg Microbes Infect* 2018;7:109.
  20. Shetty A, Raut S, Anand M, et al. Detection of Spinal TB Infection: A Retrospective Study Evaluating Comparative Diagnostic Efficacy of AFB Smear, Gene Expert, Histopathology, Culture Sensitivity and LPA Tests From a Biopsy Sample. *Int J Spine* 2022;7:1-6.
  21. Jagiasi JD, Mehta P, Ubale TV, et al. How expert is genexpert test: A study done at a tertiary care

- centre for TB spine patients. *Int J Orthop Sci* 2020;6:476-8.
22. Massi MN, Biatko KT, Handayani I et al. Evaluation of rapid GeneXpert MTB/RIF method using DNA tissue specimens of vertebral bones in patients with suspected spondylitis TB *J Orthop* 2017;14:189-91.
  23. Arockiaraj J, Michael JS, Amritanand R, et al. The role of Xpert MTB/RIF assay in the diagnosis of tubercular spondylodiscitis. *Eur Spine J* 2017;26:3162-9.
  24. Karthek V, Bhilare P, Hadgaonkar S, et al. Gene Xpert/MTB RIF assay for spinal tuberculosis-sensitivity, specificity and clinical utility. *J Clin Orthop Trauma* 2021;16:233-8.
  25. Qi Y, Liu Z, Liu X, et al. Tuberculosis-Specific Antigen/Phytohemagglutinin Ratio Combined With GeneXpert MTB/RIF for Early Diagnosis of Spinal Tuberculosis: A Prospective Cohort Study. *Front Cell Infect Microbiol.* 2022;12:781315.
  26. Zhou Z, Zheng Y, Wang L. Diagnostic accuracy of the Xpert MTB/RIF assay for bone and joint tuberculosis using tissue specimens. *Int J Infect Dis* 2021;105:224-9.
  27. Yu Y, Kong Y, Ye J, et al. Performance of conventional histopathology and GeneXpert MTB/RIF in the diagnosis of spinal tuberculosis from bone specimens: A prospective clinical study. *Clin Biochem* 2020;85:33-7.
  28. Li Z, Wang J, Xiu X, et al. Evaluation of different diagnostic methods for spinal tuberculosis infection. *BMC Infect Dis* 2023;23:695.
  29. Held M, Laubscher M, Zar HJ, et al. GeneXpert polymerase chain reaction for spinal tuberculosis: an accurate and rapid diagnostic test. *Bone Joint J* 2014;96-B:1366-9.
  30. Solanki AM, Basu S, Biswas A, Roy S, Banta A. Sensitivity and Specificity of Gene Xpert in the Diagnosis of Spinal Tuberculosis: A Prospective Controlled Clinical Study. *Global Spine J* 2020;10:553-8.
  31. Guha M, Lal H, Boruah T, et al. Clinico- radio-histopathological correlation by c-arm image-guided biopsy in spinal tuberculosis. *Indian J Orthop* 2021;55:1028-36.
  32. Li Y, Wang Y, Ding H, et al. Pathologic characteristics of spinal tuberculosis: analysis of 181 cases. *Int J Clin Exp Pathol* 2020;13:1253-61.
  33. Khanna K, Sabharwal S. Spinal tuberculosis: a comprehensive review for the modern spine surgeon. *Spine J* 2019;19:1858-70.
  34. Na S, Lyu Z, Zhang S. Diagnosis and treatment of skipped multifocal spinal tuberculosis lesions. *Orthop Surg* 2023;15:1454-67.
  35. Encarnación-Santos D, Valerievich KA, Scalia G, et al. Spondylodiscitis: Understanding pathophysiology, surgical strategies, and postoperative management - A single-center study. *J Craniovertebr Junction Spine* 2024;15:185-9.
  36. Encarnacion Santos D, Nurmukhametov R, Donasov M, et al. Management of lumbar spondylolisthesis: A retrospective analysis of posterior lumbar interbody fusion versus transforaminal lumbar interbody fusion. *J Craniovertebr Junction Spine* 2024;15:99-104.
  37. Santos DE, Bozkurt I, Nurmukhametov R, et al. The future of minimally invasive spine surgery in low-income Latin American countries. *Egypt J Neurol Psychiatry Neurosurg* 2024;60:35.
  38. Qureshi R, Puvanesarajah V, Jain A, et al. Perioperative management of blood loss in spine surgery. *Clin Spine Surg* 2017;30:383-8.
  39. Degoute CS. Controlled hypotension: A guide to drug choice. *Drugs* 2007;67:1053-76.
  40. Jamaliya RH, Chinnachamy R, Maliwad J, et al. The efficacy and hemodynamic response to Dexmedetomidine as a hypotensive agent in posterior fixation surgery following traumatic spine injury. *J Anaesthesiol Clin Pharmacol* 2014;30:203-7.
  41. Ruku R, Jamwal A, Bhadralla N, et al. Randomized open-labeled comparative

- evaluation of the efficacy of nitroglycerine, esmolol, and dexmedetomidine in producing controlled hypotension in spine surgeries. *Anesth Essays Res* 2019;13:486-91.
42. Ghodratty MR, Homae MM, Farazmehr K. Comparative induction of controlled circulation by magnesium and remifentanil in spine surgery. *World J Orthop* 2014;5:51-6.
  43. Nazir O, Wani MA, Ali N, et al. Use of dexmedetomidine and esmolol for hypotension in lumbar spine surgery. *Trauma Mon* 2016;21:e22078.
  44. Hwang W, Kim E. The effect of milrinone on induced hypotension in elderly patients during spinal surgery: a randomized controlled trial. *Spine J* 2014;14:1532-7.
  45. Crescenzi G, Landoni G, Biondi-Zoccai G, et al. Desmopressin Reduces Transfusion Needs after Surgery: A Meta-analysis of Randomized Clinical Trials. *Anesthesiology* 2008;109:1063-76.
  46. Li G, Sun TW, Luo G, et al. Efficacy of antifibrinolytic agents on surgical bleeding and transfusion requirements in spine surgery: a meta-analysis. *Eur Spine J* 2017;26:140-54.
  47. Theusinger OM, Spahn DR. Perioperative blood conservation strategies for major spine surgery. *Best Pract Res Clin Anaesthesiol* 2016;30:41-52.
  48. Chilkoti GT, Jain N, Mohta M, et al. Perioperative concerns in Pott's spine: A review. *J Anaesthesiol Clin Pharmacol* 2020;36:443-9.
  49. Dunn RN, Ben Husien M. Spinal tuberculosis: review of current management. *Bone Joint J* 2018;100-B:425-31.
  50. Bruchfeld J, Correia-Neves M, Källenius G. Tuberculosis and HIV coinfection. *Cold Spring Harb Perspect Med* 2015;5:a017871.
  51. Ding C, Hu M, Shangguan Y, et al. Epidemic trends in high tuberculosis burden countries during the last three decades and feasibility of achieving the global targets at the country level. *Front Med (Lausanne)* 2022;9:798465.
  52. Bell LCK, Noursadeghi M. Pathogenesis of HIV-1 and Mycobacterium tuberculosis co-infection. *Nat Rev Microbiol* 2018;16:80-90.
  53. Lu YJ, Barreira-Silva P, Boyce S, et al. CD4 T cell help prevents CD8 T cell exhaustion and promotes control of Mycobacterium tuberculosis infection. *Cell Rep* 2021;36:109696.
  54. Latorre I, Martínez-Lacasa X, Font R, et al. IFN- $\gamma$  response on T-cell based assays in HIV-infected patients for detection of tuberculosis infection. *BMC Infect Dis* 2010;10:348.
  55. Montales MT, Chaudhury A, Beebe A, et al. HIV-associated TB syndemic: A growing clinical challenge worldwide. *Front Public Health* 2015;3:281.
  56. Denis F. The three column spine and its significance in the classification of acute thoracolumbar spinal injuries. *Spine (Phila Pa 1976)* 1983;8:817-31.
  57. Zhao C, Luo L, Liu L, et al. Surgical management of consecutive multisegment thoracic and lumbar tuberculosis: anterior-only approach vs. posterior-only approach. *J Orthop Surg Res* 2020;15:343.
  58. Yang P, Zang Q, Kang J, et al. Comparison of clinical efficacy and safety among three surgical approaches for the treatment of spinal tuberculosis: a meta-analysis. *Eur Spine J* 2016;25:3862-74.
  59. Zhu Z, Hao D, Wang B, et al. Selection of surgical treatment approaches for cervicothoracic spinal tuberculosis: A 10-year case review. *PLoS One* 2018;13:e0192581.
  60. Wu WJ, Tang Y, Lyu JT, et al. Clinical efficacy of three surgical approaches for the treatment of cervicothoracic tuberculosis: A multicenter retrospective study. *Orthop Surg* 2020;12:1579-88.
  61. Sun D, Zhang ZH, Mei G, et al. Comparison of anterior only and combined anterior and posterior approach in treating lumbosacral tuberculosis. *Sci Rep* 2019;9:18475.

62. Wu W, Lyu J, Liu X, et al. Surgical treatment of thoracic spinal tuberculosis: a multicenter retrospective study. *World Neurosurg* 2018;110:e842-50.
63. Qureshi MA, Khaliq AB, Afzal W, et al. Surgical management of contiguous multilevel thoracolumbar tuberculous spondylitis. *Eur Spine J* 2013; 22 Suppl 4:618-23.
64. Fisahn C, Alonso F, Hasan GA, et al. Trends in spinal surgery for Pott's disease (2000-2016): An overview and bibliometric study. *Global Spine J* 2017;7:821-8.
65. May TW, Pfäfflin M. The efficacy of an educational treatment program for patients with epilepsy (MOSES): Results of a controlled, randomized study. *Epilepsia* 2002;43:539-49.
66. Gao Q, Han C, Romani MD, et al. Posterior-only debridement, internal fixation, and interbody fusion using titanium mesh in the surgical treatment of thoracolumbar tuberculosis with spinal epidural abscess: a minimum 5-year follow-up. *BMC Musculoskelet Disord* 2021;22:917.
67. Zeng Y, Chen Z, Qi Q, et al. Clinical and radiographic evaluation of posterior surgical correction for the treatment of moderate to severe post-tuberculosis kyphosis in 36 cases with a minimum 2-year follow-up. *J Neurosurg Spine* 2012;16:351-8.
68. Luo C, Wang X, Wu P, et al. Single-stage transpedicular decompression, debridement, posterior instrumentation, and fusion for thoracic tuberculosis with kyphosis and spinal cord compression in aged individuals. *Spine J* 2016;16:154-62
69. Huang Y, Lin J, Chen X, et al. A posterior versus anterior debridement in combination with bone graft and internal fixation for lumbar and thoracic tuberculosis. *J Orthop Surg Res* 2017;12:150.
70. Qiu J, Peng Y, Qiu X, et al. Comparison of anterior or posterior approach in surgical treatment of thoracic and lumbar tuberculosis: a retrospective case-control study. *BMC Surg* 2022;22:161.
71. Zhao C, Pu X, Zhou Q, et al. Can a posterior approach effectively heal thoracic and lumbar tuberculosis? Microbiology outcomes of the operative area. *J Orthop Surg Res* 2019;14:24.
72. Gao Y, Ou Y, Deng Q, et al. Comparison between titanium mesh and autogenous iliac bone graft to restore vertebral height through posterior approach for the treatment of thoracic and lumbar spinal tuberculosis. *PLoS One* 2017;12:e0175567.
73. Santos DE, Bozkurt I, Pachev M, et al. Degenerative cervical spondylolisthesis: A comprehensive systematic review in diagnosis, management, and outcomes. *Oman Med J* [Internet]. 2025 [cited 2025 Nov 26]; Available from: <https://omjournal.org/articleDetails.aspx?coType=2&aId=3916>
74. Encarnación-Santos D, Chmutin G, Chmutin E, et al. Lumbar isthmic spondylolisthesis: comparative insights into patient selection, surgical techniques, and clinical outcomes. *Sri Lanka j Surg* 2025;43:25-32.
75. Encarnacion-Santos D, Nurmukhametov R, Bozkurt I, et al. Restoring vertebral height in the treatment of multilevel vertebral compression fractures with vertebroplasty. *Egypt J Neurol Psychiatry Neurosurg* 2023;59:135.
76. Encarnación-Santos D, Chmutin G, Bozkurt I, et al. Letter to the editor regarding "minimally invasive spine surgery: An overview." *World Neurosurg* 2024;184:353-4.
77. Zeng H, Shen X, Luo C, et al. Comparison of three surgical approaches for cervicothoracic spinal tuberculosis: a retrospective case-control study. *J Orthop Surg Res* 2015;10:100.
78. Xu Z, Zhang Z, Wang X, et al. Medium-term follow-up outcomes of one-stage posterior lumbosacral or lumbopelvic fixation in the management of lumbosacral junction tuberculosis in adults. *Orthop Surg* 2021;13:2051-60.